Journal of Medical and oral biosciences
ISSN (Online): 3007-9551
ISSN (Print): 3007-9543

JMOB
Open Access DOAJ

Type: Research article
Published: 31/ 08/2024

Impact of the Immunohistochemistry on appraisal of Oral Squamous Cell Carcinoma and Cervical Lymph Nodes Metastasis

Abdulazeez Muayad Abdulkarem[1], Sabah Abdulaziz Issa[2], Sargon Shazo [3], Faeza Aftan Zghair [4]

[1] Lecturer, Department of Oral and Maxillofacial Surgery, College of Dentistry, University of ALMuthaana/ Iraq.
https://orcid.org./0009-0005-8491-4487
Email address: abdulazeez.muayad@yahoo.com
[2] Consultant, Department of Maxillofacial Sugery/ Ghazi Al-Hariri Hospital for Surgical Specialties, Bagdad / Iraq.
https://orcid.org/0009-0008-5179-2091
Sabahabulaziz@yahoo.co.uk
[3] Lecturer, University of Duhok / College of Dentistry, Iraq.
https://orcid.org/0000-0002-0048-3001
Email address: sargon.daweed@uod.ac
[4] Department of Pathology/ College of Medicine/ Aliraqia University, Bagdad / Iraq.
https://orcid.org/0000-0002-1474-1569
Email address: faizarawi@yahoo.co.uk

OPEN ACCESS

ARTICLE INFO
Received: 25/ 07/2024
Revised: 22/ 08/ 2024
Accepted: 30/ 08/2024
Publish online: 31/ 08/2024

* Corresponding Author: Dr. Abdulazeez Muayad Abdulkarem.
Email address: abdulazeez.muayad@yahoo.com
https://orcid.org./0009-0005-8491-4487

CITATION

Abdulazeez Muayad Abdulkarem, Sabah Abdulaziz Issa, Sargon Shazo, Faeza Aftan Zghair.(2024). Impact of the Immunohistochemistry on appraisal of Oral Squamous Cell Carcinoma and Cervical Lymph Nodes Metastasis. JMOB. 1;(3): 41-51.

DOI: https://doi.org/ 10.58564/jmob.49

COPYRIGHT

© 2024 Abdulazeez Muayad Abdulkarem, Sabah Abdulaziz Issa, Sargon Shazo, Faeza Aftan Zghair. This is an open-access article distributed under the terms of the Creative Commons Attribution License (CC BY-SA 4.0). The use, distribution or reproduction in other forums is allowed, provided the original author(s) and the copyright owner(s) are credited and that the original publication in this journal is cited, in accordance with accepted academic practice. No use, distribution or reproduction is permitted which does not comply with these terms.

Abstract

This study intends to compare the efficacy of traditional *hematoxylin* and eosin (H&E) staining and immunohistochemistry (IHC) in the assessment of primary oral squamous cell carcinoma and detection of lymph node (LN) occult metastasis. The primary tumor sections of 80 patients diagnosed with primary OSCC and lymph nodes of 50 patients were treated with neck dissection were subjected to routine H&E staining and IHC (CK5/6) staining. Sections were analyzed for different pathological parameters and nodal metastasis. Metastatic carcinomatous cells were observed in 14.3% of IHC sections compared to 13.5% of H&E sections. Except for tumor grade, statistical analysis for patients' age, gender, tumor diameter, tumor thickness (TT), and depth of invasion (DOI) revealed no significant correlation with lymph node status. IHC is more sensitive to detecting lymph node occult metastasis than H&E staining in conventional procedures.

Keywords: biomarkers, IHC, Squamous Cell Carcinoma, Tumor.

Introduction

Oral cancer is the commonest site of malignancy in the head and neck and accounts for more than 90% of upper aerodigestive tract malignant tumors (1-3). Oral squamous cell carcinoma (OSCC) incidences are higher in developing than in developed countries (3). It accounts for about 40% of all body cancers In India and Srilanka and only 2% in the USA and the UK (4-6). In Arab Land, oral cancer incidence varied from 10 per 100,000 in south Saudi Arabia and Yemen to 0.5 per 100,000 in Syria (6). According to Iraqi Cancer Registry (2022), oral cancer accounts for 0.78 % of all cancer, with an

CC BY-SA 4.0 Attribution-ShareAlike 4.0
https://creativecommons.org/licenses/by-sa/4.0/

incidence rate of 1.6 per 100,000 population (8). Although its incidence & prevalence in Arab land and Iraq are lower than the world-standardized rate, OSCC remains a highly disfiguring and lethal disease (9).

Genetic abnormalities are responsible for 5-10% of oral cancers, and the other 90 - 95% of cases are the consequence of environmental factors, in which tobacco (smoked, snuff, or chewing tobacco) and alcohol consumption are the major players (11,12). Human papillomaviruses (HPV- 16, HPV- 18) genomic DNA is present in nearly 25% of oral squamous cell carcinomas (10). OSCC is an age-related disease, and the majority of patients are males over 40 years (1,2). The tongue is the most common site for OSCC; however, in India and Central Asia, buccal mucosa is the most common site. In Yemen, the gingiva is the most common site for OSCC (4-7). Despite the advances in OSSC diagnosis and treatment, its 5-year survival rate is still low (50–60%) (13). Tumor size, histological grade, depth of invasion (DOI), tumor thickness (TT), surgical margins, lymph node status, and tumor stage are the consistent and reliable core parameters in determining a patient's prognosis with OSCC. Among them, lymph node-positive metastasis is the most significant prognostic factor and decision-making considering the mode of management and the extent of neck dissection (14,15). The number of involved lymph nodes and their levels in the neck, the size of the metastases, and the presence of extracapsular spread affect the outcome of neck metastasis. Positive lymph node metastasis reduces the survival rate by 50%, even in small-size tumors (16,17). Occult metastasis (micro metastasis) presents in 30% of OSCC patients with clinically negative (N0) neck (8, 9). The sensitivity of radiological modalities in the detection of node metastases varies from 40-80% for Ultrasound (U/S), magnetic resonance imaging (MRI), computed tomography (CT), and positron emission tomography (PET)-CT (18,19). Published research revealed that more than 50% of occult metastases could be detected by advanced methods other than routine histological techniques, such as immunohistochemistry (IHC) or molecular biology, the polymerase chain reaction (PCR) (18). The IHC method involves a simple immune (antigen–antibody) reaction; it has an advantage over the routinely used histochemistry staining techniques in identifying early molecular changes in tissue. Therefore, it has become a crucial and widely used technique in research and diagnostic general and oral pathology (20-22). Cytokeratins (Ck5/6) have high sensitivity, specificity, and accuracy rates in detecting micro metastasis, mainly squamous cell carcinoma (23,24). Therefore, this study intends to assess the primary OSCC and node metastasis using the immuno-histochemical technique to detect cytokeratins (Ck5/6) markers.

Materials & Methods

This study has been approved by the ethics committee of "Arab Board of Oral and Maxillofacial Surgery" / College of Dentistry / University of Baghdad/ Iraq, and the patients signed the consent form. Moreover, all ethical issues were also adhered to the ideas of the Helsinki Declaration of 1964 and its modifications. We included resected samples collected from 80 patients with primary OSSC underwent surgical treatment at (Ghazi Al-Hariri Hospital for Surgical Specialties)/in Baghdad/ Iraq, from 2015 to 2019. When more than one biopsy was performed for the same lesion, only the most representative histological section was included. Tumours originated from maxillofacial areas apart from the oral cavity and presenting inadequate material for histological review were excluded. From those 80 patients, lymph nodes of 50 patients

CC BY-SA 4.0 Attribution-ShareAlike 4.0
https://creativecommons.org/licenses/by-sa/4.0/

treated with neck dissection were subjected to routine H&E staining and IHC (CK5/6) staining. Nearly 340 tumour sections and their margins, and 672 lymph nodes from tumour mass, were processed for routine histopathological processing. The histopathological sections from collected samples was performed according to the method describe by Aziz and Zeman-Pocrnich. (2022) (25). The sample kept in 10% neutral buffered formalin (NBF) for 72 hrs. The samples were trimmed and fixed for another 48 hrs in 10% NBF to insure proper fixation. Then the samples were transferred to tissue cassette and left in 10% NBF at 60 ^{o}C till processing for 2 hrs. Then, the samples kept in tissue processer Machine (Histokinette) which transferred the samples mechanically from one reagent to another and can be done both by day and night. In this process, and prior to paraffin wax embedding and impregnation, the samples were subjected for: Fixation, Dehydration, Clearing, and Embedding in melted paraffin. Later on, blocks were made and sectioned into 4-5 micron on glass slides and stained with haematoxylin and eosin. The slides were evaluated for tumour grade, tumour thickness (TT), depth of invasion (DOI), excision margins, and lymph node metastasis. Moreover, other sections were stained with IHC (Ck5/6) according to the manufacturer's instructions (23). The results of the IHC stain were compared with their relative H&E sections. The slides were scanned and qualified by one observer who is a consultant pathologist. IHC results were categorized as negative (Staining index (SI) = 0) vs. positive (Staining index (SI) > 0) (according to the DAKO scoring system) (23). DOI was determined microscopically by measuring the length of a line, drawn perpendicular from the (horizon) of the basement membrane of the adjacent intact squamous epithelium to the deepest invasive tumour cells in the underlying tissues, regardless of the exophytic component (Figure -1A). TT was determined microscopically by measuring the entire dimension of the tumour from the top to the deepest point of invasion. Measurement was performed using a graded acetate sheet overlaid on the glass slide section (Figure -1B). Results were analysed using a standard program (Statistical Package for Social Sciences, SPSS version 17.0, Chicago, IL, US), with statistical significance level of 5% ($p<0.05$). Distribution of group variables was compared in crosstabs by Pearson Chi-square and comparison of means was performed with T test.

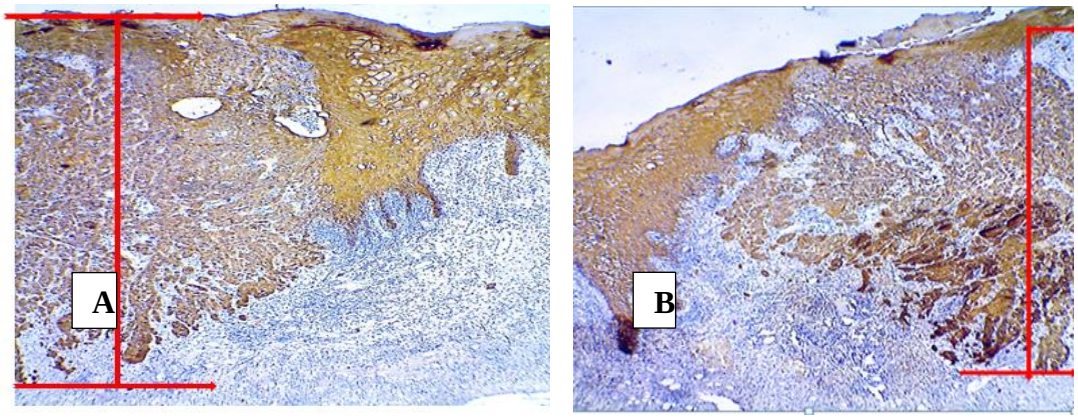

Figure 1: A: Measurement of Tumor Thickness, the length of the perpendicular line (red line) drawn from the top of the tumor to the deepest invasive tumor cells in the underlying tissues. B: Measurement of depth of invasion of the tumor, the length of the (perpendicular line) drawn from the (horizon) of the basement membrane of the adjacent intact epithelium to the deepest invasive tumor cells in the underlying tissues.

CC BY-SA 4.0 Attribution-ShareAlike 4.0
https://creativecommons.org/licenses/by-sa/4.0/

The Patients' ages ranged from 17 to 90 years, with a mean of 57.65 years. Males were equal to females. Concerning surgical margins, clear margins were detected in 50% of tumors. Positive involvement of lymph nodes was diagnosed in 56%, and the majority of the cases (48%) were at stage IVA. The clinical and pathological parameters of the studied cases are shown in Table 1.

Table.1: Clinical and Pathological Parameters of the Selected Cases

Tumor information	**No. (n= 80)**	**Percentage (%)**
Patients' age (n= 80), Mean of 57.65 years ± SD (15.2), SE (1.77)		
<30	4	5%
30 – 49	18	22.4%
50 – 69	39	48.8%
≥ 70	19	23.8%
Sex (n= 80) Male/Female Ratio = 1:1		
Female	40	50%
Male	40	50%
Histopathological grade (n= 80)		
Well differentiation	42	52.5%
Moderate differentiation	20	25.0%
Poor differentiation	18	22.5%
Lymph node involvement (n= 50)		
Positive	28	56.0
Negative	22	44.0
Pathological stage (n= 50)		
I	1	2.0
II	13	26.0
III	9	18.0
IVA	24	48.0
IVB	3	6.0
DOI (mm) (n= 50)		
≤ 5	19	38.0%
> 5	31	62.0%
TT (mm) (n= 50)		
≤ 8	39	78.0%
> 8	11	22.0%

The current study showed that the most common site of OSCC was the tongue in females and the buccal mucosa in males. The mandible and maxilla tumours were two times more female than male, while the lip tumour was four times more male than female. A statistical significant difference (P= 0.002) were seen in the histopathological grade between H & E and IHC stains (Table. 2).

Table 2: Comparison between histopathology results in H & E and IHC sections

Histopathological results	**H & E (%)** **n= 50**	**IHC (%)** **n= 50**	**P - Value**
Well	20 (40.0%)	22 (44.0%)	0.002
Moderate	25 (50.0%)	11 (22.0%)	
Poor	5 (10.0%)	17 (34.0%)	

The Journal of medical and Oral Biosciences
CC BY-SA 4.0 Attribution-ShareAlike 4.0
https://creativecommons.org/licenses/by-sa/4.0/
JMOB / Al-Iraqia University

No significant difference (P= 0.54) was found between H&E and IHC sections in assessment of lymph node metastasis. Although five lymph nodes (from five cases) showed occult metastasis in IHC sections only, and three of them upstaged from II to III (Table 2&3).

Table 3: Cases that showed differences in lymph node involvement in H & E and IHC stain

Lymph node size (cm)	P staging according to H&E[1]		P staging according to IHC[2]	
3.5	T2N0M0	II	T3N1M0	III
3	T2N0M0	II	T2N1M0	III
2.5	T2N0M0	II	T2N1M0	III
3.5	T2N2M0	IVA	T2N2M0	IVA
4.5	T3N2M0	IVA	T3N2M0	IVA

[1] Pathological staging according to H&E assessment. [2] Pathological staging according to IHC assessment.

The sensitivity of H & E stain in detecting LN metastasis was (89.3%), the specificity (100%) while the accuracy was (94%). Positive predictive value was 100% while negative predictive value was 88%. Except for the histopathological grading, no statistical significant associations ($P \geq 0.05$) were found between lymph node involvement and other parameters (Table. 4).

Table 4: Correlation between Lymph Node Status and the Clinical and Pathological Parameters

Variable	Lymph node involvement		Total (%)	P - Value
	Positive (%) n= 28	Negative (%) n= 22	n= 50	
Age (Year)				
< 30	1 (50.0%)	1 (50.0%)	2 (4.0%)	0.279
30 – 49	8 (61.5%)	5 (38.5%)	13 (26.0%)	
50 – 69	17 (63.0%)	10 (37.0%)	27 (54.0%)	
≥ 70	2 (25.0%)	6 (75.0%)	8 (16.0%)	
Sex				
Male	15 (62.5%)	9 (37.5%)	24 (48.0%)	0.407
Female	13 (50.0%)	13 (50.0%)	26 (52.0%)	
Lesion diameter (mm)				
≤ 2	0 (0)	2 (100%)	2 (4.0%)	0.195
> 2 – 4	15 (53.6%)	13 (46.4%)	28 (56.0%)	
> 4	13 (65.0%)	7 (35.0%)	20 (40.0%)	
Histopathological grade by IHC stain				
Well differentiation	7 (31.8%)	15 (68.2%)	22 (44.0%)	0.009
Moderate differentiation	9 (75.0%)	3 (25.0%)	12 (24.0%)	
Poor differentiation	12 (75.0%)	4 (25.0%)	16 (32.0%)	
Depth of invasion (mm) by IHC stain				
≤ 5	8 (42.1%)	11 (57.9%)	19 (38.0%)	0.15

The Journal of medical and Oral Biosciences
CC BY-SA 4.0 Attribution-ShareAlike 4.0
https://creativecommons.org/licenses/by-sa/4.0/
JMOB / Al-Iraqia University

> 5	20 (64.5%)	11 (35.5%)	31 (62.0%)	
Tumor thickness (mm) by IHC stain				
≤ 8	20 (51.3%)	19 (48.7%)	39 (78.0%)	0.306
> 8	8 (63.6%)	3 (36.4%)	11 (22.0%)	

No obvious brown color stain reactivity were seen in the control group sections, and the nucleus were stained with the hematoxylin counterstain. CK5/6 positive immunoreactivity reaction was indicated by brown nuclear staining. Moreover, Figures (2,3 &4) demonstrate the primary tumor sections, lymph nodes metastasis and resections margins in H&E and IHC stained sections.

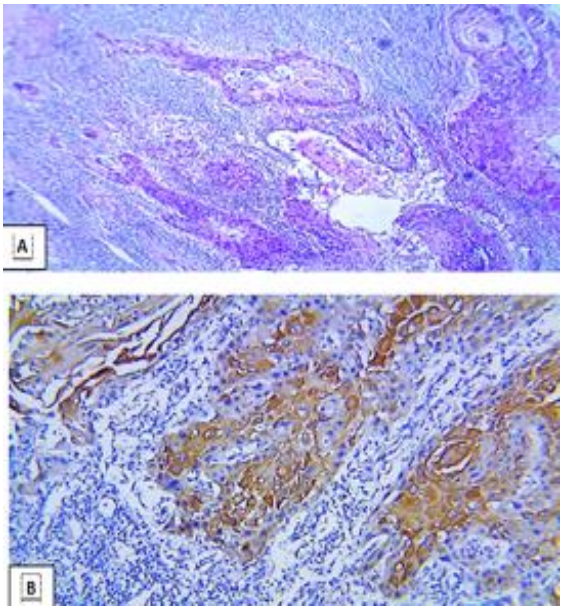

Figure. 2: Shows Squamous Cell Carcinoma well differentiated. A: H&E stain. (100X), B: IHC stain CK5/6. Positive immune expression appears as brown staining of malignant cells (100X)

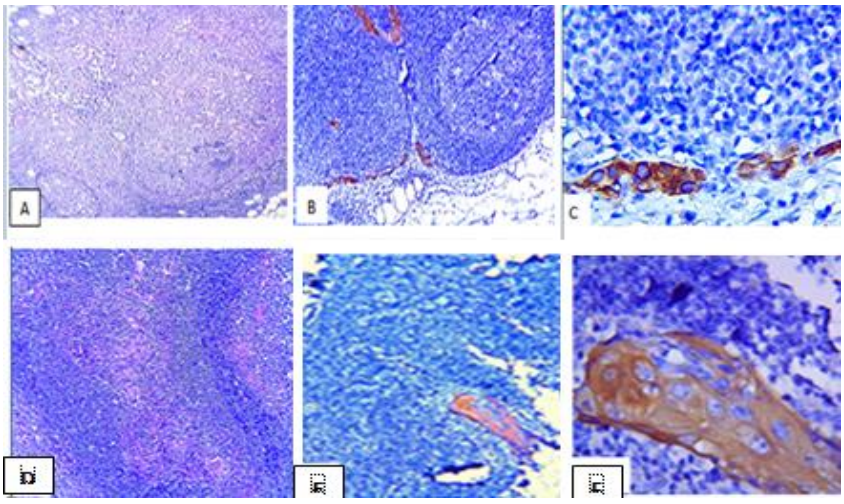

Figure. 3: Shows occult metastasis in two lymph nodes A&D (H&E sections of the two lymph nodes100X). B,C,E&F; IHC,CK5/6 at low and high-power view, confirmed the tumor invasion (IHC stain, 40X, 100X,4 0X ×200 respectively)

The Journal of medical and Oral Biosciences
CC BY-SA 4.0 Attribution-ShareAlike 4.0
https://creativecommons.org/licenses/by-sa/4.0/
JMOB / Al-Iraqia University

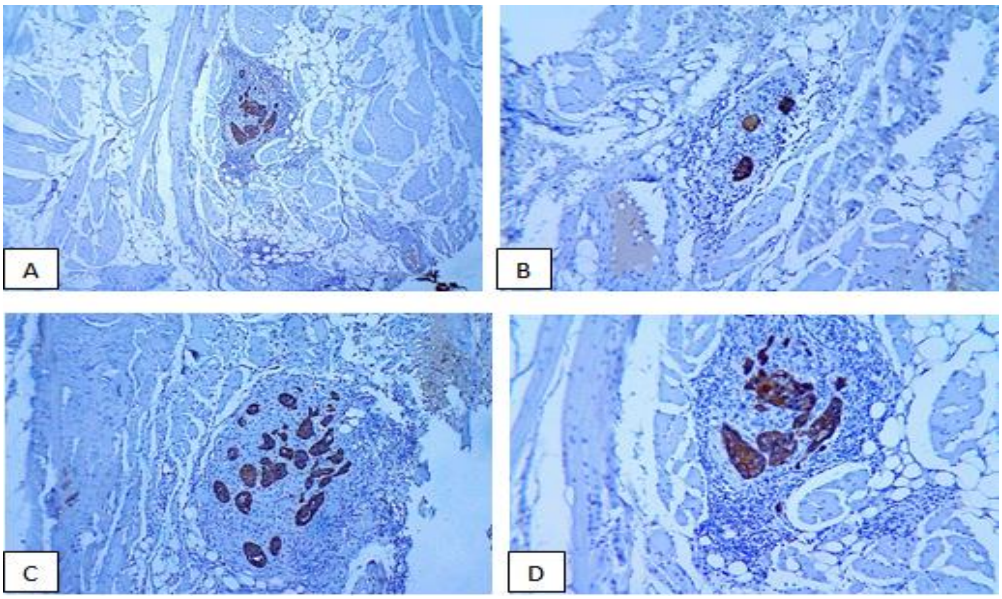

Figure. 4: Tumor cells close to resection margins. A, B, C & D: Shows clusters of tumor cells close to resection margins (1–5 mm from the free margin). (IHC CK5/CK6, Magnification 40X, 40X, 40X,100X respectively)

Discussion

The increasing occurrence of OSSC is creating an alarming situation and concern worldwide. Though the histological investigation remains the gold standard technique to diagnose the OSCC (26), several efforts are being made to identify more specific markers of this tumour's biological nature and aggressiveness (27). In this study, the mean age was 57.65 years, and the peak (48.8%) was between 50 - 69 years. However, 27.4% of patients were below the age of 50 years. The tumour was equally distributed in males and females, and most of the cases (27.5%) were encountered at the tongue, followed by the buccal mucosa (23.8%). Half of the cases (52.5%) were well differentiated, and 72% were at the advanced stage. These results agree with previous reports from Iraq, Yemen, Saudi Arabia, Arabian, and worldwide reports (22, 28- 31), but differ from the findings in India and Central East Asia (4, 9). OSSC in young and female patients suggests that factors (other than tobacco and alcohol) may contribute to the development of OSCC, like family history and HPV infection (22). Additionally, it indicates the need for histological assessment of suspicious oral lesions in high-risk patients as young as in their second decade (32). The site of OSSC can be correlated with the habit and method of tobacco consumption (4,9,32 31). The mixed carcinogens with saliva tend to pool at the bottom of the mouth, which is covered by thin non-keratinized squamous epithelium, providing less protection against the carcinogen (33). In this study, the histological grading significantly correlated to lymph node status. This is contrary to other studies. The disagreements are related to intra and inter-observer variation in the grading of squamous cell carcinoma, tumoral heterogeneity from one area to another, and the fact that WHO grading is subjective rather than objective and lacks a scoring system (34- 36). In this study, there was a significant difference between H&E and IHC grading, and this may be related to the sharp contrast in IHC colours, giving more clear details of different tumour cell populations. Although many studies reported a significant correlation between DOI and lymph node status (and fewer studies on TT), ours revealed no significant correlation

CC BY-SA 4.0 Attribution-ShareAlike 4.0
https://creativecommons.org/licenses/by-sa/4.0/

between DOI or TT and lymph node status. This disagreement in the results can be attributed to the different definitions for these two parameters, the lack of a standardized measurement method, and the tumour biopsy might only sometimes contain the most invasive cells which accurately reflect the DOI or TT (34- 39). Although no significant difference was found in DOI measurement by H&E and IHC sections, however (22%) of cases got higher DOI in IHC by (0.5 – 2mm), and one case upstaged from II to III. Four cases (8%) were reported with clear margins by H&E stained sections found to be "close to" IHC staining. Published articles revealed that node-negative OSCC, with "close" margins, was associated with aggressive behaviour & poor survival (30, 35). All lymph nodes detected positive by H and E staining were also positive by IHC. However, five nodes from five patients showed positive metastasis following IHC staining, which was first termed negative in H&E stained sections. Thus, three cases (6%) changed from No to N1 and upstaged from II to III. Out of the 672 nodes, occult metastasis was detected in 14.3% of total nodes by IHC compared to 13.5% by H&E staining. Considering IHC as the standard for detecting occult metastasis, the sensitivity of H&E detection was 89.3%, and the accuracy was 94%. Although our results were statistically non-significant but clinically, they are important as they correlated with patient survival. The minor variations in lymph node status, surgical margins, histopathological grade, and DOI in IHC results affect decision-making regarding postoperative treatment (mainly radiotherapy), also the rate of tumour recurrence, prognosis, and patient survival significantly in patients with early-stage OSCC. The major drawback of this study was the difficulty in performing programmed follow-ups of the patients during the study period to assess prognosis and patient survival. However, the strength of this study is that the proposed model, based on the application of IHC apart from its coast, is well available, being simple and easy to use in routine clinical and Lab practice.

Conclusions

In conclusion, this study demonstrated some of the potential benefits of IHC in assessing OSCC and its efficiency and accuracy in detecting occult metastasis in compare to routine H&E . We recommend performing further studies with programmed follow-ups of the patients to assess prognosis and patient survival.

DECLARATIONS:

Funding

The author would like to approved that this work was received no financial support from any authorities. The work is self-supported.

Competing interests statement

The authors approved that there is no conflict of interest from any parties upon publication of this manuscript.

Ethics statement

All authors approved that this research follows the journal's ethical guidelines as appeared on the journal's author guidelines page.

CC BY-SA 4.0 Attribution-ShareAlike 4.0
https://creativecommons.org/licenses/by-sa/4.0/

Author contributions

All the authors contributed equally for designing research, data collection, data acquisition, data analysis, reporting and manuscript preparation.

Acknowledgments

The authors would like to acknowledge all supporter for helping in completion of this study.

Data availability

Datasets related to this article will be available upon request to the corresponding author.

References

1. Johnson NW & Amarasinghe HK. Epidemiology and aetiology of head and neck cancers. Bernier J. Head and Neck Cancer: Multimodality Management. Springer. 2016; 1: 1-58.
2. Dhanuthai K, Rojanawatsirivej S, Thosaporn S, Kintarak S, Subarnbhesa A, Darling M, Kryshtalskyj E, *et al*. Oral cancer: A multicenter study. Med Oral Pathol Oral Cir Bucal. 2018; Jan; 23(1): e23–e29.
3. Karima Al Salihi, Ihsan Abdullah, Ang SL. Histological implication of p53 gene expression in oral squamous cell carcinoma . Journal of Cellular Cancer. 2016; 8(1):60-69.
4. Rai HC and Ahmed J. Clinicopathological correlation study of oral squamous cell carcinoma in a local Indian population. Asian Pac J Cancer Prev. 2016; 17: 1251–1254.
5. Han AY, Kuan EC, Mallen-St et al. Epidemiology of squamous cell carcinoma of the lip in the United States: a population-based cohort analysis. JAMA Otolaryngol Head Neck Surg. 2016; 142(12): 1216–1223.
6. Cancer Research UK. (2016, June). The Mouth and Oropharynx.
7. Al-Jaber A, Al-Nasser L, & El-Metwally A. Epidemiology of oral cancer in Arab countries. Saudi Med J. 2016; 37(3): 249–255)
8. CANCER TODAY data visualization tools for exploring the global cancer burden in 2020 https://gco.iarc.fr/today/data/factsheets/populations/368-iraq-fact-sheets.pdf.
9. Malayk K, Ronak N, Tapan GM, and Chintan D. Oral cancer: Etiology and risk factor: A review. Cancer Research and Therapeutics J. 2016; 12: 2, 458- 463.
10. Hellen-Bandeira-de-Pontes Santos T, dos Santos KG, Paz AR, *et al*. Clinical findings and risk factors to oral squamous cell carcinoma in young patients: a 12-year retrospective analysis.Med Oral Patol Oral Cir Bucal. 2016; 21(2): e151.
11. McIlwain WR, Sood AJ, Nguyen Sh A, and Day TA. Initial Symptoms in Patients with HPV-Positive and HPV-Negative oropharyngeal Cancer. JAMA Otolaryngology–Head & Neck Surgery.2014; 140: 5.
12. Al-Salihi KA, Ang SL, Azlina A, Farini M, Jaffar H. Immunohistochemical and molecular genetic analysis of p 53 in oral squamous cell carcinoma (scc) in Hospital University Science Malaysia: a preliminary study. Braz. J. Oral Sci. 2008; 23;7(24):1476-1483.

CC BY-SA 4.0 Attribution-ShareAlike 4.0
https://creativecommons.org/licenses/by-sa/4.0/

13. Nayanar SK, Tripathy JP, Duraisamy K, Babu S. Prognostic efficiency of clinicopathologic scoring to predict cervical lymph node metastasis in oral squamous cell carcinoma. J Oral Maxillofac Pathol. 2019;23:36-42
14. Iqbal H, Jamshed A, Bhatti AB, Hussain R, Jamshed S, Irfan M, Hameed N, Illyas A. Five-year follow-up of concomitant accelerated hypofractionated radiation in advanced squamous cell carcinoma of the buccal mucosa: a retrospective cohort study. Biomed Res Int. 2015;2015:963574. doi: 10.1155/2015/963574. Epub 2015 May 14. PMID: 26075278; PMCID: PMC4446464.
15. Loeffelbein D, Ritschl LM, Gu¨ ll FD, et al. Influence of possible predictor variables on the outcome of primary oral squamous cell carcinoma: a retrospective study of 392 consecutive cases at a single center. Int J Oral Maxillofac Surg. 2017; 46(4):413–421.
16. Givi B, Eskander A, Awad MI, *et al*. Impact of elective neck dissection on the outcome of oral squamous cell carcinomas arising in the maxillary alveolus and hard palate. Head Neck. 2016 Apr; 38 (Suppl 1).
17. Kelner N, Vartanian JG, Pinto CA, *et al*. Does elective neck dissection in T1/T2 carcinoma of the oral tongue and floor of the mouth influence recurrence and survival rates? Br J Oral Maxillofac Surg. 2014; 52(7): 590–597.
18. Pałasz P, Adamski L, Chrząstek MGS, Starzyńska A, and Studniarek M. Contemporary Diagnostic Imaging of Oral Squamous Cell Carcinoma – A Review of Literature. Pol J Radiol. 2017; 82: 193–202.
19. Silva RK De, Siriwardena BS MS, Samaranayaka A, Abeyasinghe WA MUL, Tilakaratne WM. A model to predict nodal metastasis in patients with oral squamous cell carcinoma. PLoS One. 2018; 13(8): 201-217.
20. Dhawan I, Sandhu SV, Bhandari R, Sood N, Bhullar RK, Sethi N. Detection of cervical lymph node micrometastasis and isolated tumor cells in oral squamous cell carcinoma using immunohistochemistry and serial sectioning. J Oral Maxillofac Pathol. 2016;20:436-44
21. Lewis JS, Chernock RD, and Bishop JA. Squamous and Neuroendocrine Specific Immunohistochemical Markers in Head and Neck Squamous Cell Carcinoma: A Tissue Microarray Study. Head Neck Pathol. 2018; 12(1): 62–70.
22. Habib A Manal, Habib A Huda, Hussain A Israa, Karima Al-Salihi. Expression of TIMP-2 in HPV-16 infected oral squamous cell carcinoma in patients in Iraq. Expression of TIMP-2 in HPV-16 infected oral squamous cell carcinoma in patients in Iraq. Braz J Oral Sci. 2016; 15(1):51-56. http://dx.doi.org/10.20396/bjos.v15i1.8647123
23. Vasca V, Vasca E, Freiman P, Marian P, Luce A, Mesolella M, *et al*. Keratin 5 expression in squamocellular carcinoma of the head and neck. Oncology Letters 2014; 8: 2501-2504.
24. Zhu S, Schuerch C, Hunt J. Review and updates of immunohistochemistry in selected salivary gland and head and neck tumors. Arch Pathol Lab Med. 2015 Jan;139(1):55-66. doi: 10.5858/arpa.2014-0167-RA. PMID: 25549144.
25. Aziz S J, Zeman-Pocrnich C E. Tissue Processing. In: Del Valle, L. (eds) Immunohistochemistry and Immunocytochemistry. Methods in Molecular Biology, 2022; vol 2422. Humana, New York, NY. https://doi.org/10.1007/978-1-0716-1948-3_4
26. Badvi JA, Kulsoom J, Ujjan IU, et al. Recent techniques for diagnosis of oral squamous cell carcinoma. EC Microbiology. 2017; 5(5):165–168.
27. D'souza Sh, and Addepalli V. Preventive measures in oral cancer: An overview. Biomedicine & Pharmacotherapy. 2018; Vo 107: 72-80.
28. Taha IA, and Younis WH. Clinicopathological analysis of oral squamous cell carcinoma in Iraq During period (2001-2013). J Bagh College Dentistry. 2015; Vol: 27(2).

The Journal of medical and Oral Biosciences
CC BY-SA 4.0 Attribution-ShareAlike 4.0
https://creativecommons.org/licenses/by-sa/4.0/
JMOB / Al-Iraqia University

29. Halboub ES, Abdulhuq M, and Al-Mandili A. Oral and pharyngeal cancers in Yemen: a retrospective study. Eastern Mediterranean Health Journal (EMHJ). 2012;Vol. 18: No. 9 (985 – 991).
30. Yang X, Song X, Chu W, *et al.* Clinicopathological characteristics and outcome predictors in squamous cell carcinoma of the maxillary gingiva and hard palate. Int J Oral Maxillofac Surg. 2015; 73(7): 1429–1436.
31. Chi AC, Day TA, Neville BW. Oral cavity and oropharyngeal squamous cell carcinoma--an update. CA Cancer J Clin. 2015 Sep-Oct;65(5):401-21. doi: 10.3322/caac.21293. Epub 2015 Jul 27. PMID: 26215712.
32. Ng JH, Iyer NG, Tan MH, Edgren G. Changing epidemiology of oral squamous cell carcinoma of the tongue: A global study. Head Neck. 2017; Feb; 39(2):297-304.
33. Sekine J Nakatani E, Hideshima K IwahashiT and Sasaki H. Diagnostic accuracy of oral cancer cytology in a pilot study. Diagn Pathol. 2017; 12: 27.
34. Jadhav KB, Gupta N. Clinicopathological prognostic implicators of oral squamous cell carcinoma: need to understand and revise. N Am J Med Sci. 2013 Dec;5(12):671-9. doi: 10.4103/1947-2714.123239. PMID: 24404549; PMCID: PMC3877528.
35. Zhang Q, Chen K, Qiu J, Tan Y, Zhuo X, Jia Y, Cao1 Z, Yan J and Wei1 Y.. Difference of WHO Pathological Grading among Different Depths in Oral Squamous Cell Carcinoma and Its Clinical Significance. Clin Surg. 2017; 2: 1506.
36. Dissanayake U. Malignancy grading of invasive fronts of oral squamous cell carcinomas: correlation with overall survival. Transl Res Oral Oncol. 2017; 2: 1–8.
37. Kuan EC, Clair JM, Badran KW, *et al.* How does depth of invasion influence the decision to do a neck dissection in clinically N0 oral cavity cancer? Laryngoscope 2016; 126(3):547–548.
38. Almangush A, Bello IO, Coletta RD, *et al.* For early-stage oral tongue cancer, depth of invasion and worst pattern of invasion are the strongest pathological predictors for locoregional recurrence and mortality. Virchows Arch. 2015; 467(1):39–34.
39. Yamada S, Kurita H, Shimane T, *et al.* Estimation of the width of free margin with a significant impact on local recurrence in surgical resection of oral squamous cell carcinoma. Int J Oral Maxillof Surg. 2016; 45(2): 147–152.

CC BY-SA 4.0 Attribution-ShareAlike 4.0
https://creativecommons.org/licenses/by-sa/4.0/