



OPEN ACCESS

ARTICLE INFO

Received: 03/10/2024
Revised: 29/10/2024
Accepted: 02/11/2024
Publish online: 10/01/2024

* Corresponding Author: Kasim Obaid Hussein Al-Ali.

Email: Kasim.abead@mu.edu.iq

<https://orcid.org/0000-0003-0345-7906>

CITATION

Kasim Obaid Hussein Al-Ali, Haider Yihya Kurkoosh, Abbas khudair Hadi Al-Bawi. (2025). The Burn Wounds Treatment; A Clinical Comparison Study between Moist Exposed Burn Ointment and Silver Sulphadiazine. JMOB. 2,(1): 01-10.

<https://doi.org/10.58564/jmob.80>

COPYRIGHT



© 2025 Kasim Obaid Hussein Al-Ali, Haider Yihya Kurkoosh, Abbas khudair Hadi Al-Bawi. This is an open-access article distributed under the terms of the [Creative Commons Attribution License \(CC BY-SA 4.0\)](https://creativecommons.org/licenses/by-sa/4.0/). The use, distribution or reproduction in other forums is allowed, provided the original author(s) and the copyright owner(s) are credited and that the original publication in this journal is cited, in accordance with accepted academic practice. No use, distribution or reproduction is permitted which does not comply with these terms.

Burn Wounds Treatment; A Clinical Comparison Study between Moist Exposed Burn Ointment and Silver Sulphadiazine

Kasim Obaid Hussein Al-Ali ^{1*} ,
Haider Yihya Kurkoosh ², Abbas khudair
Hadi Al-Bawi ³

Introduction

Burns are the fourth most common type of trauma. According to the World Health Organization, the estimated number of thermal burns is 6.6 million injuries and 300

¹ College of Medicine / Al Muthanna University/ Al-Hussein Teaching Hospital / Samawa

<https://orcid.org/0000-0003-0345-7906>

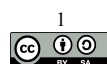
² General Surgeon / Al-Hussein Teaching Hospital / Samawa
Email: Haiderkarkoosh19@gmail.com

³ General Surgeon/Al-Hussein Teaching Hospital/Samawa.
Email: Ibawybas@gmail.com

Abstract

Burn injuries are considered one of the major sources of trauma that might lead to substantial morbidity and mortality. Severe burns cause multiple organ dysfunction and even sometimes organ failure, leading to debility and subsequent scarring that affects the quality of life and mental health. Consequently, this study is designed to compare the outcomes of two burn treatment modalities in patients suffering from burn injuries who were admitted to the Burn Unit / AL-Hussein Teaching Hospital / Samawa / Al-Muthanna Governorate. A clinical study was established during the period from December 2018 to January 2022 60 patients of both sexes suffered from different burn injuries. All patients are treated with Moist Exposed Burn Ointment -MEBO- or with covered classic methods using silver sulphadiazine cream dressings. Follow-up of treated patients is done to evaluate the treatment outcome. Our study included 44 burned and 16 scalded cases of different age groups, with second and third burn degrees extending on different body surface areas ranging from 30-60% in males and 30-70% in females. Of 60 patients, 40 females (67%) were between 10 and 40 years old, and 20 males (33%) were between 3 and 36 years old. The mortality percentages were 7 (23.3%) and 2 (6.6 %) cases out of a total of 60 patients for the conventional method and MEBO-treated group, respectively. Sepsis was observed in most dead cases, manifested by foul-smelling wound discharge and necrotic non-viable wound tissues, in addition to pneumonia and bronchitis. *Pseudomonas sp*, *Klebsiella sp*, and *Proteus sp* were isolated from these cases by culture and sensitivity tests. In conclusion, this study showed that the MEBO cream application in treating burned injuries revealed dramatic curative hopeful results with less liability for infective and septic complications compared with the conventional method, represented by the Sulphadiazine cream application. The authors recommend using treatment in burn units instead of using the routine old conventional method to avoid the expected morbidity and mortality and gain acceptable cosmetic results.

Keywords: Burn, MEBO, Conventional method, silver sulphadiazine.



thousand deaths each year universally. About 95% of burn deaths are reported to occur in low-income communities due to using of open fires for heating, lighting, and cooking, lack of education, and poor access to medical care(1). Burn is defined as damage to the skin and its underlying tissues due to a variety of causes, such as radiation, caustic elements, electricity, and heat. Burn causes variable degrees of damage depending on the severity, depth of burn, and type of the causative agent (2,3). Burn is a coagulative necrosis of the skin and deeper tissues with related structures leading to three zones of tissue damage(4,5). Major burns include more than 20% of body surface area, causing pathological and physiological responses in most body systems such as immune, nervous, respiratory, and cardiovascular systems. Most burned patients were suffering from hypovolemic shock due to loss of plasma. The modern medical regime used in burn treatment restores respiration and maintains hemodynamic stability in most severe thermal wounds. Most burn-associated death occurs from wound infection (5–7), if adequate facilities are accessible (3). Bacterial infection and dead elements in burned tissue are a nidus for bacterial proliferation. Systemic antibiotic application is impaired in such cases by the occlusion of vessels in neighboring areas. Several non-surgical methods are available for treating superficial and partial-thickness burns; these include biosynthetic and inorganic dressings and topical treatment. Topical treatment of burn wounds is of great importance in treating injuries; it prevents death from invasive infection and evaluates treatment outcomes like the development of hypertrophic scars and keloids. Silver compounds have been used as a conventional topical treatment of burn injuries since 1960. Various silver compounds, such as silver sulphadiazine 1% [SSD] suspension, penetrate eschar to a lesser extent and have less activity against *Pseudomonas* but show lethal power against a wide range of microbes, even fungi (3,8). A Chinese burn ointment called MEBO (Moist Exposed Burn Ointment) has been registered with a USA-patented formulation since 1995. It is formulated from natural ingredients, including sesame oil, Beeswax, *Coptis chinensis*, *Pheretima aspergillum*, *Phellodendron amurense*, *Scutellaria baicalensis*, and beta-sitosterol (9). MEBO is approved to act as an analgesic and antibacterial, though its beta-sitosterol element has an anti-inflammatory influence (9) . Additionally, sesame oil extract has a free radical scavenging and antioxidant capacity; therefore, it is beneficial in speeding wound healing (10–12). A review of the literature revealed scarce publications regarding the clinical application of MEBO in the treatment of burn injuries in burn units in Iraq. Therefore, this study aims to compare the outcome of silver sulphadiazine ointment versus MEBO cream in treating patients suffering from burned injuries in the Burn unit / AL-Hussein Teaching Hospital / Samawa / Al-Muthanna.

Materials and Methods

Subjects

This study has been approved by the research committee / College of Medicine / Al Muthanna University. Additionally, patients were asked to sign an informed consent form before participating in this study.

This clinical study was done during the period from December 2018 to January 2022 on 60 patients suffering from burn injuries. The inclusion criteria of subjects were patients who suffered from second and third-degree burns, patients who cooperated with the researcher, and those patients residing near the health services. While, the exclusion criteria from the study was those patients with first and fourth-degree, patients not



cooperative with the researcher, and those residing far from the health services. The patients included were 40 females aged 10-40 years and 20 males aged between 3-36 years. The past medical problems were recorded for each patient; only six diabetic cases were discovered, two males and 4 females. One-third (20 patients) of cases belong to affluent wealthy families, one-third belong to an average lifestyle, and the other third are poor patients. The patients were divided randomly into two groups, each with 30 patients. The patients were treated with Moist Exposed Burn Ointment -MEBO and silver sulphadiazine SSD dressings for the first and second groups. Follow-up for each treated patient was reported to evaluate the treatment outcome regularly. The hospital burn unit / AL-Hussein Teaching Hospital / Samawa / Al-Muthanna is isolated and well-air-conditioned. Its sterilization level is acceptable due to the frequent admission of clean, removing of contaminates, and sometimes septic cases; septic cases are admitted to a special strict isolation room. This unit is also provided with adequately trained staff and sub-staff and daily aseptic sanitation measures. Every patient received urgently through the hospital emergency department shifted toward the burn unit (if indicated for admission). The treatment plan for each patient was prepared to avoid any septic foci or sources of contamination and infection. Each patient is dressed in a unique sterile gown in a specific bathroom explicitly established for washing and cleaning from any debris, contaminants, and cloth remnants and then kept in an isolated room provided with specialized well-equipped beds; then a proper application of local cream preparation (MEBO or silver sulphadiazine dressings according to treatment group) applied evenly over the affected areas; intravenous fluid lines fixed and kept running with crystalloid solution mainly Lactated Ringer solution according to a universally applied formula (Parkland formula) as:

Body weight (kg) X percentage of burn X 4=Total fluid requirement / 24 hours

(half of the total fluid will be given during the first 8 hours and the other half during the next sixteen hours). The parenteral antimicrobial regimen is mainly active against gram-positive microbes, and parenteral painkillers started immediately. Moreover, close follow-ups were accompanied by monitoring vital signs, urine output, and renal function, complete blood analysis was done as a baseline checkup. During treatment, each patient was subjected to a once-daily whole body tap water shower, then three times daily (eight hours) lubrication with burn cream according to treatment groups. All patients in the burn unit are subjected to changing their dress and bed sheets once daily. They are also supplied with a high-protein diet and liquid diet, and regular programmed daily physiotherapy of the affected parts is provided to prevent expected stiffness and future motion difficulties.

Results

According to gender, most of sample was female (67%) and (41.66%) from those patients was (21 – 30) years of age. Additionally, the selected level of income was equal for each level (33.33%) (Table.1 & Figure,1).

The second category of patients also was female (67%) with (41.66%) of them was (21 – 30) years of age (Table.2).

The reported patients medical data were including the: Body Surface Area (BSA), Diabetes and Degree of Burn and Gender (Table.3). Nearly half of sample (46.66%) has



(30%) burn according body surface area and (10%) of sample have diabetes mellitus and equally (50%) selection dependent on degree of burn.

Table.1: Distribution of cases according to the socio-demographic data (Age and Gender, and level of Income)

Variable	Classes	Frequency	Percentage
Gender	Male	40	67
	Female	20	33
	Total	60	100
Age	1 - 10	7	11.66
	11 – 20	8	13.33
	21 - 30	25	41.66
	31 -40	20	33.33
	Total	60	100
Level of Income	Rich Life Style	20	33.33
	Moderate Life Style	20	33.33
	Poor Life Style	20	33.33
	Total	60	100

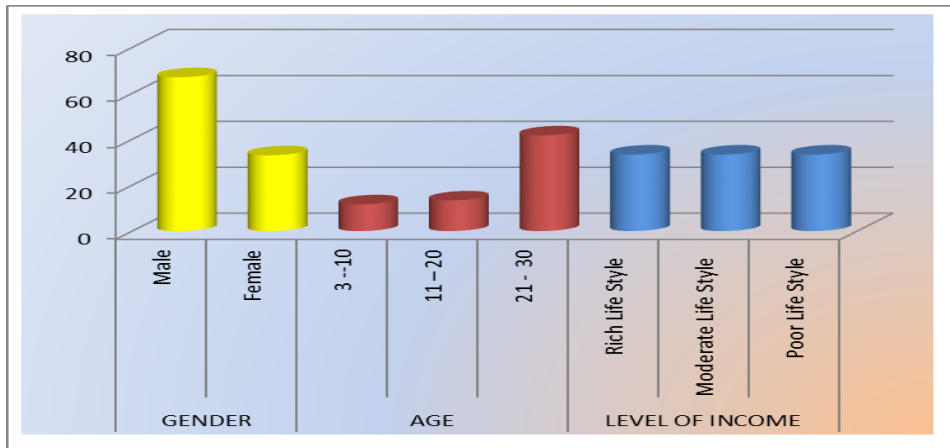


Figure. 1: show most of sample was female (67%) and (41.66%) from sample' age was (21 – 30) and selected level of income equal for each level (33.33%).

Table 2: Distribution according the socio-demographic data between (age and gender)

Variable	Items	Male		Female		Total	
		Frequency	Percentage	Frequency	Percentage	Frequency	Percentage
Age	1 - 10	5	8.33	2	3.33	7	11.66
	11 – 20	2	3.33	6	10.00	8	13.33
	21 - 30	3	5	22	36.66	25	41.66
	31 -40	10	16.66	10	16.66	20	33.33
	Total	20	33.33	40	66.66	60	100

Table.3: Distribution according to medical data (Body Surface Area (BSA), Diabetes and Degree of Burn) and Gender

Items		Male		Female		Total	
Variable	Classes	Frequenc y	Percentag e	Frequenc y	Percentag e	Frequenc y	Percentag e
Body Surface Area (BSA)	30%---	10	16.66	18	30	28	46.66
	40%---	10	16.66	12	20	22	36.66
	50%---	0	0	7	11.66	7	11.66
	60%---	0	0	3	5	3	5
	Total	20	33.33	40	66.66	60	100
Diabetes	Diabetes	2	3.33	4	6.66	6	10
	No diabetes	18	30	36	60	54	90
	Total	20	33.33	40	66.66	60	100
Degree of Burn	Second Degree	10	16.66	20	33.33	30	50
	Third Degree	10	16.66	20	33.33	30	50
	Total	20	33.33	40	66.66	60	100

The percentages of healed patients with MEBO and Sulphdiazine were (90%), and (76.66%) respectively (Table.4 & Figure.2).

Table. 4: Distribution according to the groups (Sulphdiazin Group and MEBO Group) and mortality or healing.

Items		Sulphdiazin Group		MEBO Group		Total	
Mortality	Dead	7	11.66	2	3.33	9	15
	Healed	23	38.33 (76.66% in group)	28	46.66 (90% in group)	51	85
	Total	30	50	30	50	60	100

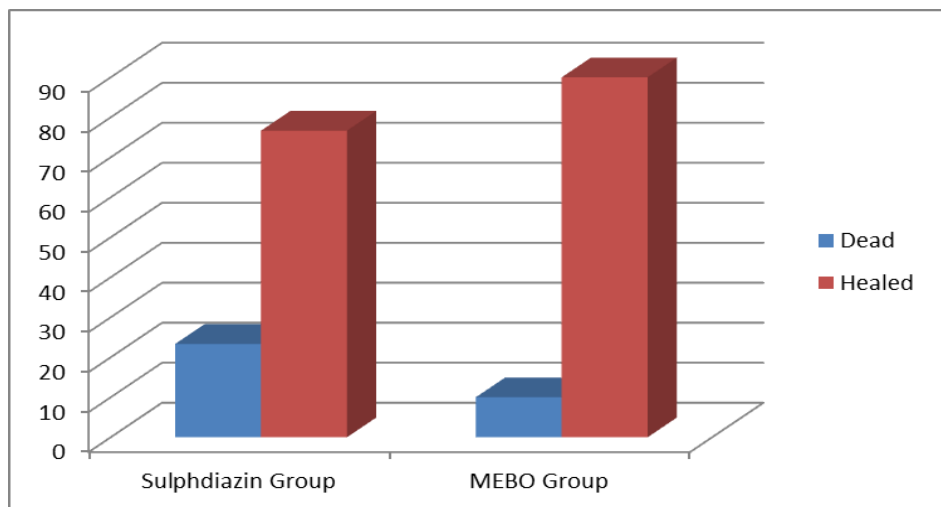


Figure. 2: Shows healing percentages : (90%) with MEBO, and (76.66%) with Sulphdiazine.

Out of 60 patients who suffered from different degrees of burn injuries, there were 40 (67%) and 20 (33%) female and male, respectively. Additionally, the patient's ages ranged between 10-40 and 3-36 years for females and males, respectively. The mortality percentages were 2 (6.6 %) and 7 (23.3%) out of 30 patients for each group as MEBO and silver sulphadiazine dressing, respectively. However, most dead cases suffered from various problems such as advanced septicemia, pneumonia, bronchitis, renal impairment, and sepsis, which were manifested by foul-smelling wound discharge and necrotic non-viable wound tissues. *Pseudomonas sp.*, *Klebsiella sp.*, and *Proteus sp.* were isolated in these cases. In addition, some cases suffered from level of consciousness disturbances and respiratory insufficiency manifested by tachypnea and decreased oxygen saturation. Nonetheless, all survival patients in group 1 who were treated with MEBO revealed dramatic curative improvements. There was an acceleration in wound healing accompanied by less liability for infective and septic complications and subsequent better and acceptable cosmetic results. Later, all patients revealed early start of daily exercise, routine activities, and rehabilitation. The surviving patients in group 2 who were treated with the silver sulphadiazine dressing method suffered from delayed wound healing, more liability for keloid development, and various disabilities.

Discussion

Burns cause various injuries worldwide. Treatment of burn injuries is very challenging, expensive, and accompanied by degrees of threat to the patient's life (2,13). Consequently, it is essential to find an appropriate method and a proper substance to cover burn injuries that encourage and speed the healing process, control the growth of microorganisms, and prevent dryness. Various topical applications have been advocated and used for a long time in treating different degrees of burn wounds. Different aspects are used to evaluate the therapeutic outcome of burn wounds, including the pain scale, degree of disability, scarring, total expenses, and survival rate. The results of the current study revealed a noticeable improvement in the healing of burn injuries in patients treated with MEBO and speeding in the healing period accompanied by a reduction in the mortality rate (6.6 %). In comparison, patients treated with silver sulphadiazine dressing revealed more mortality rate (23.3%) and delayed in the healing period. These results are compatible with previously published studies (11,14–19). All these studies approved that no scars were left after wound treatment with MEBO. Nevertheless, a thin, soft scar was developed in the third-degree burn wound treated with MEBO. Those researchers approved the main mechanisms of the curative effects of MEBO, where they found a fast wound regeneration and division of the dermal cells in the survived dermal tissues. Additionally, wound restoration occurred based on the filling up of the MEBO for the impairment of dermis tissues(19,20). They also found apparent curative effects and reductions in the course of treatment. The shortest average course of the disease was 0.63 years, while the longest average course was 8.08 years; according to the statistical analysis of Health Technology Assessment Section (MaHTAS) Medical Development Division/ Malaysian (21), which was done on 4954 cases. Moreover, this report approved that the shortest and longest average curing times were 10.59 days and 21.58 days, respectively. Local treatment with MEBO revealed reduced pain and complete regenerative healing of the deep second-degree wounds (22,23). Moreover, it also encourages local resistance to infection and reduces bacterial toxicity; consequently, MEBO effectively prevents and controls wound infection. Previous studies showed that

MEBO generated a moist milieu and provided an excellent nutrition supply to encourage the proliferation and differentiation of epithelial stem cells from the epithelial and relevant tissues in the residual fat layer and finally cured the wounds to full-thickness (24). Since 1960, silver compounds have been the backbone of topical burn care (25). Silver ion released from SSD kills virtually all known microbes, including yeasts. It kills on contact by blocking their cellular respiratory pathways (25). However, silver nitrate causes electrolyte imbalance; additionally, it is absorbed into the bloodstream, altering acid-base levels. Mafenide acetate causes pain and may increase opiate requirements, while SSD causes neutropenia (8,26). On the other hand, the application of MEBO revealed soothing wounds using a moisture-retaining oil, berberine, one of its active agents (27). It also suppresses microbial proliferation and promotes rapid re-epithelization (28).

Conclusion

This study approved the improvement in the treatment of burn wounds using the newly applied method MEBO at Al-Hussain Teaching Hospital / A-Muthanna governorate. Moreover, an apparent clinical improvement is seen in the general condition of most treated patients subjected to broad surface area affection by burns or scalds with the subsequent life-saving sequel. The study also approved a dramatic curative improvement with MEBO application with less liability for infective and septic complications compared with the conventional method in the treatment of burned injuries. The authors recommend using the regime applied with group 1, which showed much better clinical outcomes regarding local improvement and healing results documented by a noticeable number of surgeons and other clinicians concerned with the treatment of such tragedy.

Acknowledgement

I would like to express my sincere gratitude and special thanks to my patients, their relatives and teaching hospital staff for their thankful patience, and full cooperation. Also I am grateful to my friends who contributed ideas and perspectives that enriched the project. Thank you everyone for shaping this project and enhancing my learning experience.

Funding

The author did not receive any source of fund or financial support neither from governmental nor from private sector.

Competing interest statement

Up till the end and establishment of this project I would like to announce honestly that no conflict of interest was faced whether concerned with the achievement and publishing of this article.



Ethics statement

It is of my pleasure to declare that the author approved that this research follows the journal's Attach Ethic Approval guidelines as appeared on the journal's author guidelines page.

References

1. Schaefer TJ, Szymanski KD. Burn Evaluation and Management. Study Guide from StatPearls Publishing, Treasure Island (FL). 2017 Jul 15;PMID: 28613492.
2. Al Salihi KA, Fatima Atiya Kareem, Hayder Merhej Watban, Noor AbdulHadi Hasan. Amniotic membranes as biological dressings for treatment of severe experimental burns in rabbit. *Mirror of research in veterinary sciences and animals*. 2017 Nov 10;3(1):1–12.
3. Jewo PI, Fadeyibi IO, Babalola OS, Saalu LC, Benebo AS, Izegbu MC, et al. A Comparative Study of the Wound Healing Properties of Moist Exposed Burn Ointment (MEBO) and Silver Sulphadiazine. . *Ann Burns Fire Disasters* 2009 Jun 30;22(2):79-82 . 2009 Jun 30;30(2):79–82.
4. Nielson CB, Duethman NC, Howard JM, Moncure M, Wood JG. Burns. *Journal of Burn Care & Research*. 2017;38(1):e469–81.
5. Chen YY, Wu PF, Chen CS, Chen IH, Huang WT, Wang FD. Trends in microbial profile of burn patients following an event of dust explosion at a tertiary medical center. *BMC Infect Dis*. 2020 Dec 4;20(1):193.
6. Trop M, Herzog SA, Pfuerscheller K, Hoebenreich AM, Schintler M V., Stockenhuber A, et al. The past 25 years of pediatric burn treatment in Graz and important lessons been learned. An overview. *Burns*. 2015 Jun;41(4):714–20.
7. Lin TC, Wu RX, Chiu CC, Yang YS, Lee Y, Lin JC, et al. The clinical and microbiological characteristics of infections in burn patients from the Formosa Fun Coast Dust Explosion. *Journal of Microbiology, Immunology and Infection*. 2018 Apr;51(2):267–77.
8. Fatima Q ul ain, Ahmed N, Siddiqui B, Rehman A ur, Haq I ul, Khan GM, et al. Enhanced Antimicrobial Activity of Silver Sulfadiazine Cosmetotherapeutic Nanolotion for Burn Infections. *Cosmetics*. 2022 Sep 9;9(5):93.
9. Hassan A, Ahmed E, Ghalwash D, Elarab AE. Clinical Comparison of MEBO and Hyaluronic Acid Gel in the Management of Pain after Free Gingival Graft Harvesting: A Randomized Clinical Trial. *Int J Dent*. 2021 Aug 14;2021:1–10.



10. Wang J, Hao L, Zhou X, He W, Hu M. Clinical application of traditional Chinese medicine moisture exposed burn ointment in the treatment of facial soft tissue defect. *J Cosmet Dermatol*. 2022 Jun 18;21(6):2481–7.
11. Jeschke MG, van Baar ME, Choudhry MA, Chung KK, Gibran NS, Logsetty S. Burn injury. *Nat Rev Dis Primers*. 2020 Feb 13;6(1):11.
12. Shady NH, Soltane R, Maher SA, Saber EA, Elrehany MA, Mostafa YA, et al. Wound Healing and Antioxidant Capabilities of *Zizyphus mauritiana* Fruits: In-Vitro, In-Vivo, and Molecular Modeling Study. *Plants*. 2022 May 24;11(11):1392.
13. Al-Salihi KA, Ajeel AA, Ali KOH. Successful treatment of dog's bite wounds in two sheep by a caprine Amniotic Membrane with long-term follow-up. *Adv Anim Vet Sci*. 2019;7(3).
14. Mason SA, Nathens AB, Byrne JP, Diong C, Fowler RA, Karanicolas PJ, et al. Increased Rate of Long-term Mortality Among Burn Survivors. *Ann Surg*. 2019 Jun;269(6):1192–9.
15. Bayuo J, Agbenorku P, Amankwa R, Agbenorku M. Epidemiology and outcomes of burn injury among older adults in a Ghanaian tertiary hospital. *Burns Open*. 2018 Apr;2(2):98–103.
16. Rowan MP, Cancio LC, Elster EA, Burmeister DM, Rose LF, Natesan S, et al. Burn wound healing and treatment: review and advancements. *Crit Care*. 2015 Dec 1;19(1):243.
17. Cords CI, van Baar ME, Pijpe A, Nieuwenhuis MK, Bosma E, Verhofstad MHJ, et al. Short-term and long-term increased mortality in elderly patients with burn injury: a national longitudinal cohort study. *BMC Geriatr*. 2023 Jan 17;23(1):30.
18. Gueugniaud PY. Management of severe burns during the 1st 72 hours. In *Annales francaises d'anesthesie et de reanimation*. 1997;16(4):354–65.
19. Kamel Nasreen Kader. MEBO Ointment Acts As Antioxidant in Burns Patients. *Annals of the Romanian Society for Cell Biology* . 2021;18703–10.
20. Wang J, Hao L, Zhou X, He W, Hu M. Clinical application of traditional Chinese medicine moisture exposed burn ointment in the treatment of facial soft tissue defect. *J Cosmet Dermatol*. 2022 Jun 18;21(6):2481–7.
21. HEALTH TECHNOLOGY ASSESSMENT SECTION MEDICAL DEVELOPMENT DIVISION MINISTRY OF HEALTH MALAYSIA SERIAL NO 015 /2011 MEDICAL DEVELOPMENT DIVISION MINISTRY OF HEALTH MALAYSIA 015/2011. MEBO BURN OINTMENT. 2011.
22. Yang R, Wang J, Chen X, Shi Y, Xie J. Epidermal Stem Cells in Wound Healing and Regeneration. *Stem Cells Int*. 2020 Jan 29;2020:1–11.



23. Zheng A, Ma H, Liu X, Huang Q, Li Z, Wang L, et al. Effects of Moist Exposed Burn Therapy and Ointment (MEBT/MEBO) on the autophagy mTOR signalling pathway in diabetic ulcer wounds. *Pharm Biol.* 2020 Jan 1;58(1):124–30.
24. Hartinger CG, Zorbas-Seifried S, Jakupec MA, Kynast B, Zorbas H, Keppler BK. From bench to bedside – preclinical and early clinical development of the anticancer agent indazolium trans-[tetrachlorobis(1H-indazole)ruthenate(III)] (KP1019 or FFC14A). *J Inorg Biochem.* 2006 May;100(5–6):891–904.
25. Maghsoudi H, Monshizadeh S, Mesgari M. A Comparative Study of the Burn Wound Healing Properties of Saline-Soaked Dressing and Silver Sulfadiazine in Rats. *Indian Journal of Surgery.* 2011 Jan 18;73(1):24–7.
26. Saraf S. Moist exposed burn ointment: Role of alternative therapy in the management of partial-thickness burns. *Indian J Dermatol Venereol Leprol.* 2010;76(4):415.
27. Ang ES, Lee ST, Gan CS, See P, Ng LH, Machin D. The role of alternative therapy in the management of partial thickness burns of the face--experience with the use of moist exposed burn ointment (MEBO) compared with silver sulphadiazine. *Ann Acad Med Singap* 2000 Jan;29(1):7-10 PMID: 10748957. 2000 Jan;29(1):7–10.
28. ALAA EBRAHIM SAEED, BATOOL AMIN JADDOUE, DERGHAM MAJEED HAMEED. Evaluation of Nurses practice About Postoperative Wound Care At AlDiwaniya Teaching Hospital.